

CASE REPORT

Prosthetic Management of Endodontically Restored Tooth

¹Milap H Karia, ²Hiral M Karia

ABSTRACT

Restoration of badly broken endodontically treated teeth is a common problem in restorative dentistry. Such teeth often require additional support from the root canal by means of a post and core restoration. In cases where tooth structure is significantly lost, full coverage restorations for posterior teeth are necessary to achieve proper tooth form and function. Badly broken teeth with minimal or no crown structure require added retention and support. The Richmond crown can be a good treatment alternative for restoration of such teeth. The Richmond crown was introduced in 1878 and incorporated a threaded tube in the canal with a screw-retained crown. It was later modified to eliminate the threaded tube and was redesigned as a one-piece dowel and crown.

This case report shows restoration of badly mutilated posterior teeth with Richmond crown.

Keywords: Badly mutilated teeth, Dowel and core, Endodontically treated, Richmond crown.

How to cite this article: Karia MH, Karia HM. Prosthetic Management of Endodontically Restored Tooth. *Int J Oral Care Res* 2017;5(2):156-159.

Source of support: Nil

Conflict of interest: None

INTRODUCTION

The goal of restorative dentistry and endodontics is to retain the natural teeth with maximal function and pleasing esthetics.¹ It is generally agreed that the successful treatment of a badly broken tooth with pulpal disease depends not only on endodontic therapy but also on good prosthetic reconstruction of the tooth following endodontic therapy.²

The primary purpose of a post is to retain a core in a tooth that has lost its coronal structure extensively.^{3,4}

There are many techniques of restoring a badly broken molar tooth after successful endodontic treatment, which should be complemented by a sound coronal restoration. This should ideally meet the requirements of function and esthetics. There are two main categories of post: Custom

fabricated and prefabricated. In the late 19th century, the "Richmond crown," a single-piece post-retained crown with a porcelain facing, was engineered to function as a bridge retainer. Richmond crown is not post and core system but it is customized, cast able post and crown system as both are single unit and casted together. It is easier to make cast metal restorations with the aid of posts for retention and lasting service. However, whenever possible, the metal can be camouflaged by veneering with tooth-colored restorations.⁵⁻⁸

CASE REPORT

A 40-year-old patient reported to the Department of Prosthetic Dentistry, Pacific Dental College, Udaipur, Rajasthan, India, experiencing pain in the right back tooth region (Fig. 1).

On examination of oral cavity, it was found that tooth 46 had extensive caries with crown fracture at the distolingual cusp.

It was tender on percussion and palpation. Intraoral periapical radiograph revealed deep caries involving the pulp space with fracture on the distolingual cusp.

No periapical changes were noted. Root canal treatment was initiated under local anesthesia (Fig. 2).

Access opening was done and working length was determined using root canal files. The pulpal tissue remnants were extirpated with barbed broach, pulp space preparation was done with k-files and nickel titanium rotary files (protaper size – SX, S1, S2, F1, F2, F3), irrigated with sodium hypochlorite (3%) and saline to flush out the debris. The root canals were dried with paper points

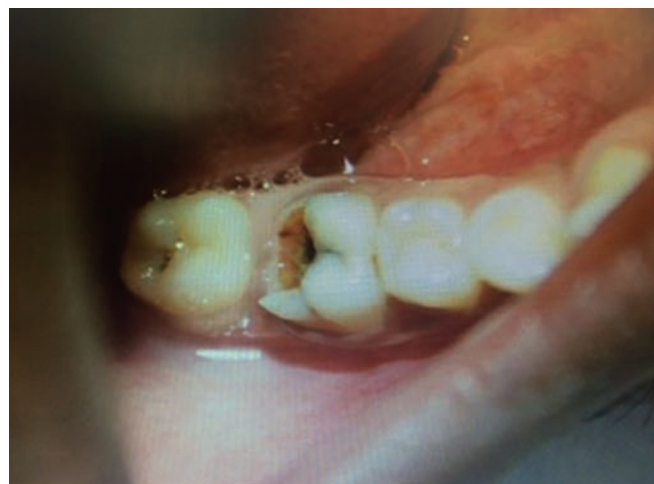

Fig. 1: Pretreatment view

^{1,2}Senior Lecturer

^{1,2}Department of Prosthodontics, Darshan Dental College & Hospital, Udaipur, Rajasthan, India

Corresponding Author: Milap H Karia, Senior Lecturer Department of Prosthodontics, Darshan Dental College & Hospital, Udaipur, Rajasthan, India, Phone: +918690771870 e-mail: milapkaria@gmail.com

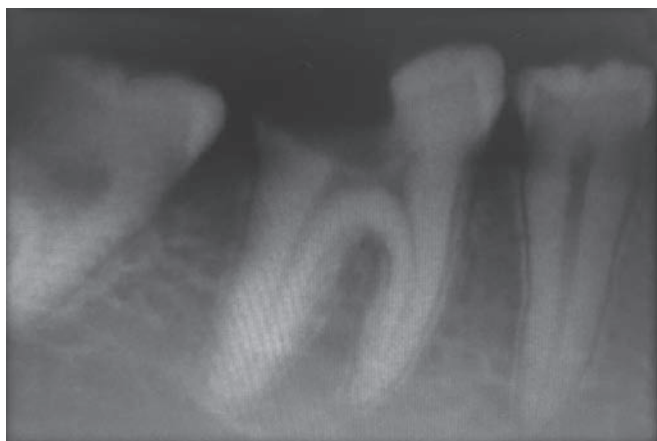

Fig. 2: Preoperative radiograph

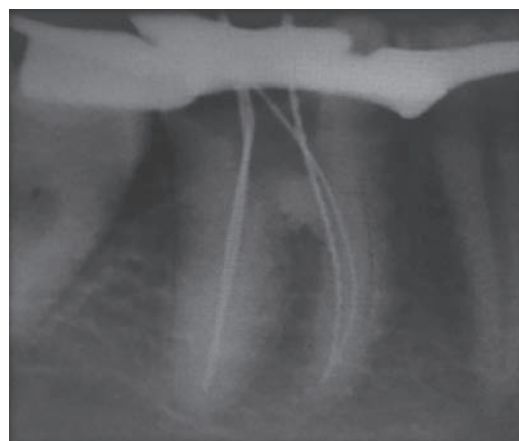


Fig. 3: Working length determination

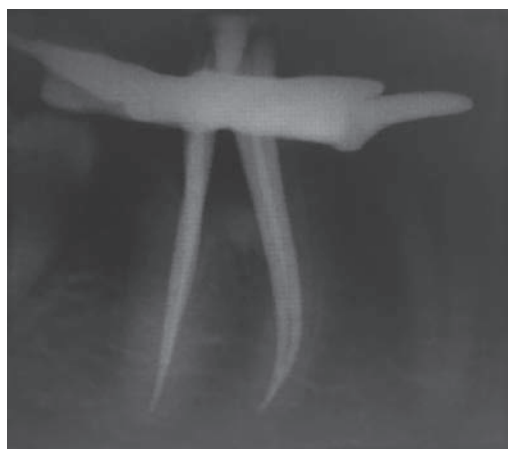

Fig. 4: Master cone selection

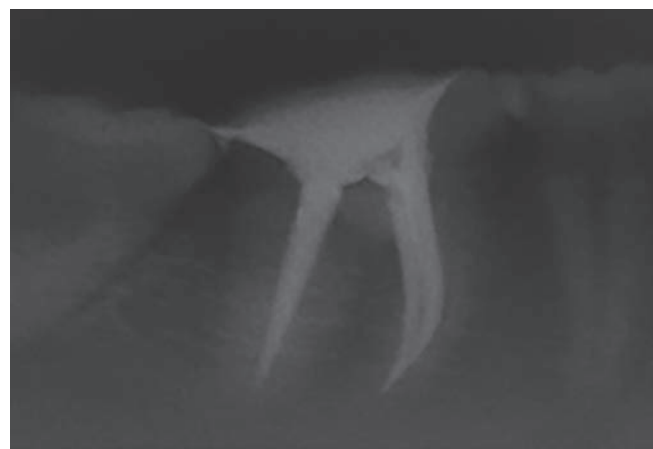


Fig. 5: Obturation

coated with zinc oxide eugenol sealer using lentilspiral, and finally obturation was done using gutta-percha (protaper size – F3) (Figs 3 to 5).

In this case report, Richmond crown was planned as it can be a better option instead of prefabricated posts because of major loss of tooth structure and lack of occlusal clearance for conventional porcelain-fused metal crown.⁹

Gutta-percha was removed from distal canal with Gates Glidden drill (size 1 to 4); care was taken not to disturb the apical seal. Post space preparation was done with peso reamer drill up to size #04 (Fig. 6).

Root preparation in the distal canal was done as conservatively as possible. For making final impression, the distal canal was coated with light body impression material (Impressiv), and then a small piece of orthodontic wire coated with light body was placed in the canal. Later light body was injected around the prepared tooth, putty impression material (Perfit) was loaded in stock tray, and final impression was made (Fig. 7).

The impression was examined for defects in recording of post space. It was then poured with die stone and wax pattern was fabricated. Metal try-in was done before ceramic buildup (Fig. 8). Finally, cementation was done with resin cement (RelyXTM).

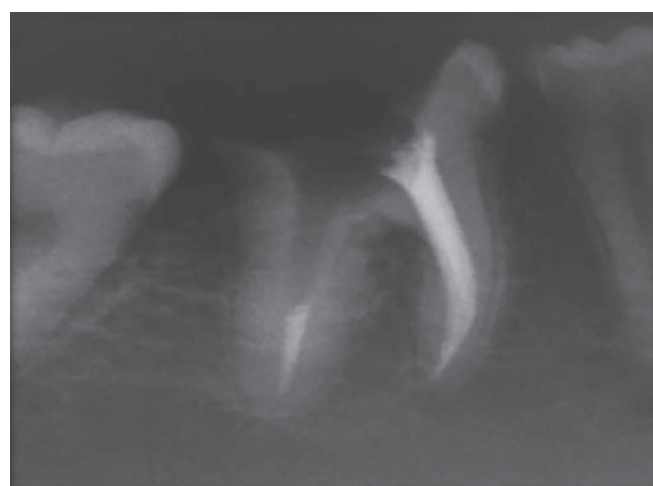


Fig. 6: Post space preparation

DISCUSSION

For more than 250 years, clinicians have written about the placement of posts in the roots of teeth to retain restorations. As early as 1728, Pierre Fauchard described the use of “tenons”, which were metal posts screwed into the roots of teeth to retain bridges.¹⁰

In the mid-1800s, wood replaced metal as the post material, and the “pivot crown”, a wooden post fitted

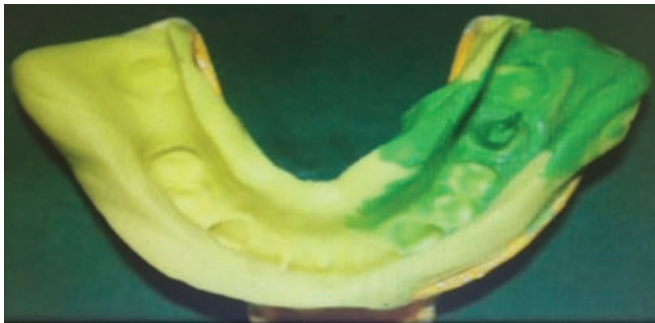


Fig. 7: Final impression of post space

to an artificial crown and to the canal of the root, was popular among dentists.¹⁰

In the late 19th century, the “Richmond crown”, a single-piece post-retained crown with a porcelain facing, was engineered to function as a bridge retainer. Richmond crown is not post and core system but it is customized, cast able post and crown system as both are single unit and casted together.⁵⁻⁸

Design includes casting of post and crown coping as single unit over which ceramic is fired and cemented inside canal and overprepared crown structure having same path of insertion. Ferrule collar is incorporated to increase mechanical resistance, retention apart from providing antirotational effect. A major technical drawback of this design is excessive tooth preparation in making two different axis parallel, which results in weakening of tooth and also this design increases stresses at post apex causing root fracture.

Few indications for Richmond crown are grossly decayed or badly broken single tooth where remaining crown height is very less and in cases with steep incisal guidance.

The advantages of this design are custom fitting to the root configuration, little or no stress at cervical margin, high strength, availability of considerable space for ceramic firing and incisal clearance, elimination of cement layer between core and crown, so reducing chances of cement

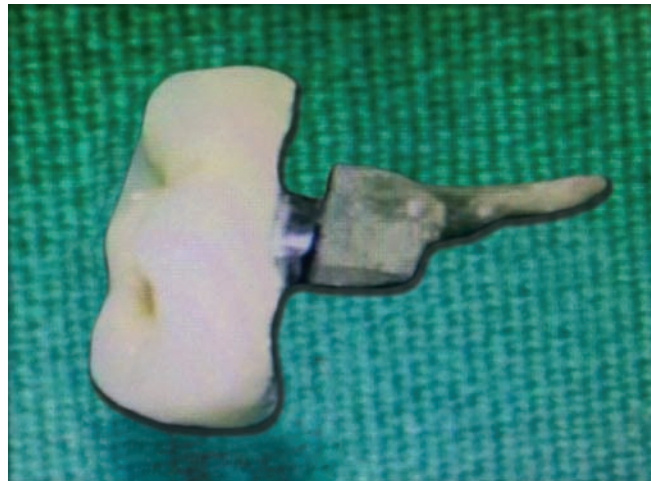

Fig. 8: Metal try-in and Richmond crown

failure. However, certain disadvantages include its time-consuming nature, requiring multiple appointments, high cost, high modulus of elasticity than dentin (10 times greater than natural dentin),¹¹ less retentive than parallel-sided posts, and acting as a wedge during occlusal load transfer, and if the ceramic part fractures, then it is difficult to retrieve, which can finally lead to tooth fracture.

A single-unit post and core crown restoration has various advantages over its multiple unit counterparts. When the post and core are two separate entities, flexion of the post under functional forces stresses the post/core interface, resulting in separation of core due to permanent deformation of post.¹²

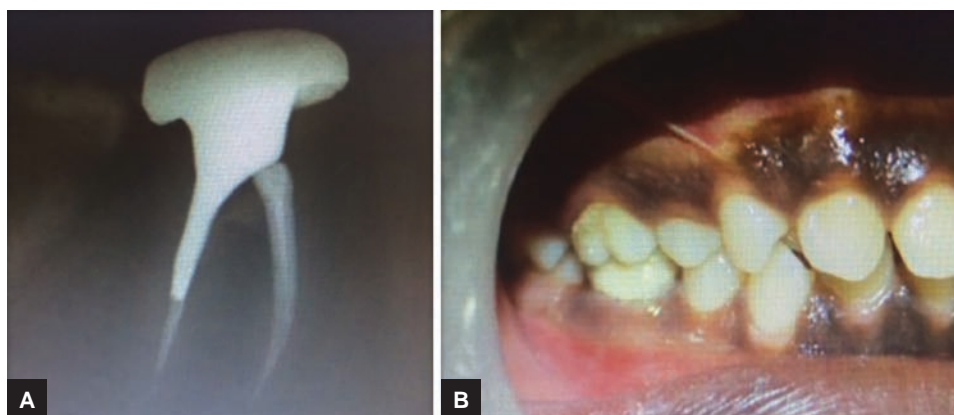
Breakdown of core eventually results in caries or dislodgement of crown. The combined effects of thermal cycling, fatigue loading, and aqueous environment test the bond between materials and cause breakdown of the materials over a period of time. Therefore, it is desirable to unite the post, core, and crown in one material for long-term stability.¹³ By decreasing the number of interfaces between components, the single-unit restoration helps to achieve a “monoblock effect” (Figs 9 to 11).¹⁴

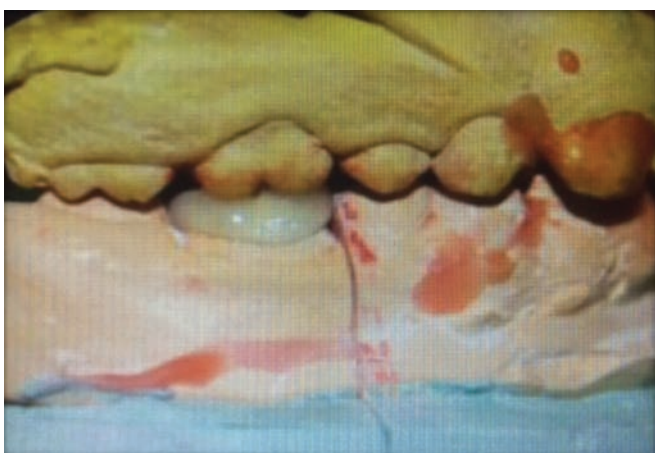

Fig. 9: Occlusion on cast

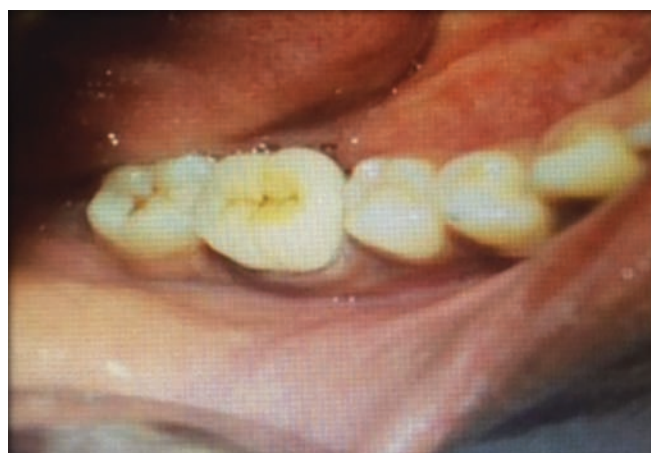

Fig. 10: Cementation



Figs 11A and B: Posttreatment and Richmond crown in occlusion

CONCLUSION

There are situations in which Richmond crown is indicated or contraindicated, as well as features that should be considered in deciding that one is the treatment of choice for restoring a grossly decayed or badly broken tooth. Richmond crown can be used as a treatment option for the badly broken endodontically treated tooth with less occlusal clearance but should be used judiciously.

REFERENCES

1. Rosenstiel SF, Land MF, Fujimoto J. Contemporary fixed prosthodontics. 2nd ed. St. Louis: Mosby 1995; p. 238.
2. Weine FS. Endodontic therapy. 6th ed. St. Louis: Mosby; 2004. p. 553-561.
3. Bartlett SO. Construction of detached core crowns for pulpless teeth in only two sittings. J Am Dent Assoc 1968 Oct;77(4): 843-845.
4. Cheung W. Properties of and important concepts in restoring the endodontically treated teeth. Dent Asia 2004 Sep-Oct; 40-47.
5. Smith CT, Schuman N. Prefabricated post-and-core systems: an overview. Compend Contin Educ Dent 1998 Oct;19(10):1013-1020.
6. Hudis SI, Goldstein GR. Restoration of endodontically treated teeth: a review of the literature. J Prosthet Dent 1986 Jan;55(1):33-38.
7. Fernandes AS, Dessai GS. Factors affecting the fracture resistance of post-core reconstructed teeth: a review. Int J Prosthodont 2001 Jul-Aug;14(4):355-363.
8. Gogna R, Jagadish S, Shashikala K, Keshava Prasad BS. Restoration of badly broken, endodontically treated posterior teeth. J Conserv Dent 2009 Jul-Sep;12(3):123-128.
9. Agarwal A, Chadha M, Kumar RV, Somani P, Jain P. Richmond crown – a conventional approach for restoration of badly broken posterior teeth. J Dent Peers 2013 Apr;1(1):35-39.
10. Smith CT, Schuman NJ, Wasson W. Biomechanical criteria for evaluating prefabricated post-and-core systems: a guide for the restorative dentist. Quintessence Int 1998 May;29(5):305-312.
11. Freedman G. The carbon fibre post: metal-free, post-endodontic rehabilitation. Oral Health 1996 Feb;86(2):23-26, 29-30.
12. Libman WJ, Nicholls JI. Load fatigue of teeth restored with cast posts and core and complete crowns. Int J Prosthodont 1995 Mar-Apr;8(2):155-161.
13. Ahn SG, Sorensen JA. Comparison of mechanical properties of various post and core materials. J Korean Acad Prosthodont 2003;41(3):288-299.
14. Vinothkumar TS, Kandaswamy D, Chanana P. CAD/CAM fabricated single-unit all-ceramic post-core-crown restoration. J Conserv Dent 2011 May;14(1):86-89.